

# A case of unprovoked venous thromboembolism in a marathon athlete presenting atypical sequelae: What are the chances?

C. M. Hull<sup>1</sup>, C. L. Hopkins<sup>2</sup>, N. J. Purdy<sup>1</sup>, R. C. Lloyd<sup>2</sup>, J. A. Harris<sup>2</sup>

<sup>1</sup>Institute of Life Science 1, College of Medicine, Swansea University, Swansea, UK, <sup>2</sup>Penmaen Residence, University Health Centre, Swansea, UK

Corresponding author: Claire M. Hull, PhD, Swansea University, Institute of Life Science, College of Medicine, Singleton Park, Swansea, Swansea SA2 8PP, UK. Tel: +44 1792 295417, Fax: +44 1792 602147, E-mail: c.m.hull@swansea.ac.uk

Accepted for publication 1 May 2014

Marathon runners are exposed to multiple thrombogenic risk factors including dehydration and hemoconcentration, injury and inflammation, long-distance travel between events, and contraceptive usage. However, despite awareness about thromboembolism and several case reports detailing life-threatening hypercoagulopathies in athletes, the prevalence of venous thromboembolism in marathon runners remains uncharted. There is a lack of data and evidence-based guidelines for these athletes and for healthcare providers, including general medical practitioners and sports physicians. We present an episode of unprovoked deep vein thrombosis (DVT) and pulmonary embolism (PE) in a female marathon athlete who pre-

sented with atypical sequelae over the course of 8 months, and identify some “easy-to-miss” warning signs and symptoms. Through dialogue with the patient regarding their personal questions and anxieties surrounding idiopathic DVT-PE, we identify a clear need for more accessible information and comprehensive research concerning the detection, prevalence, and long-term management of venous thromboembolism in athletes. We discuss the possibility that being an athlete might constitute a more significant risk factor for venous thromboembolism than is currently estimated by commonly used diagnostic protocols and conclude that there is quite possibly a need for more specific clinical guidelines for athletes in this area.

In 2011, news that top American tennis player Serena Williams had suffered a pulmonary embolism (PE) sparked media and public speculation not least because venous thromboembolism (VTE), the collective term for deep vein thrombosis (DVT) and PE, is widely associated with physical inactivity (Goldhaber & Morrison, 2002; Goldhaber & Fanikos, 2004). At a time when the global healthcare burden of obesity is escalating, the benefits of moderate and regular exercise for the population at large are undisputable. However, for the marathon athlete who trains intensively and for long periods of time, several possibly thrombogenic risk factors (e.g., dehydration and hemoconcentration, injury and inflammation, long-distance travel between events, and contraceptive usage) exist (Meyering & Howard, 2004; Hanke et al., 2010; Hull & Harris, 2013); that these could and should inform specialist healthcare policy for athletes has recently received attention (Grabowski et al., 2013; Hull & Harris, 2013). However, many overlooked, unasked, and unanswered questions still remain. For example, the Wells criteria (Tables 1 and 2) are widely used to determine risk scores for DVT (Wells et al., 2003) and PE (Wells et al., 2000) in the adult population at large. Despite their potential exposure to multiple thrombogenic risk factors (Fig. 1), being an athlete is not a specific risk criterion for VTE.

Here we present an episode of unprovoked DVT-PE in a female marathon athlete who presented with atypical sequelae over the course of 8 months, and identify some “easy-to-miss” warning signs and symptoms. Through dialogue with the patient regarding their personal questions and anxieties surrounding their idiopathic DVT-PE, we identify a clear need for more accessible information and comprehensive research concerning the detection, prevalence, and long-term management of venous thromboembolism in athletes. We discuss the possibility that being an athlete might – in itself – constitute a more significant risk factor for venous thrombosis and venous thromboembolism than is currently estimated by commonly used diagnostic protocols and conclude that there is quite possibly a need for more specific clinical guidelines for athletes in this area.

## Case report

### Initial assessment

A 29-year-old female athlete (weight 52 kg, height 166 cm, body mass index 18.9) presented with exertional dyspnea that commenced only upon intense exercise (sprint work rather than distance training) and resolved rapidly following cessation. The athlete was a marathon road-runner who trained daily (average distances of

Table 1. Wells scoring system for deep venous thrombosis

Clinical feature	Score
Active cancer (treatment ongoing, within 6 months, or palliative)	1
Paralysis, paresis, or recent plaster immobilization of the leg	1
Recently confined to bed for $\geq 3$ days or major surgery within 12 weeks requiring general or regional anesthesia	1
Localized tenderness along the distribution of the deep venous system	1
Entire leg swollen	1
*Calf swelling at least 3 cm larger than asymptomatic side	1
Pitting edema confined to the symptomatic side	1
*Collateral superficial veins (non-varicose)	1
Previously documented deep venous thrombosis	1
†An alternative diagnosis at least as likely as deep venous thrombosis	-2
Likelihood of deep venous thrombosis	
Total score of $\geq 2$ : likely	
Total score of $\leq 1$ : unlikely	

Adapted from information in Wells et al. (2003).

\*Semi-applicable to female athlete at point of assessment in the minor injury unit (but not at specified cut-off).

†Criterion most applicable to female athlete at point of assessment.

Table 2. Wells scoring system for pulmonary embolism

Clinical feature	Score
*Clinical signs and symptoms of deep venous thrombosis (minimum of leg swelling and pain with palpation of the deep veins)	3
An alternative diagnosis that is less likely than pulmonary embolism	3
Heart rate $> 100$ beats/min	1.5
Immobilization for $> 3$ days or surgery in the previous 4 weeks	1.5
Previous deep venous thrombosis or pulmonary embolism	1.5
Hemoptysis	1
Malignancy (on treatment, treated in the past 6 months or palliative)	1
Likelihood of pulmonary embolism	
Total score of $> 4$ : likely	
Total score of $\leq 4$ : unlikely	

Adapted from information in Wells et al., (2000).

\*Criterion most applicable to female athlete at point of assessment in the minor injury unit.

between 10 and 20 km) and exercised with light weights and bicycle work in the gymnasium three times a week. Her vital signs were stable with an oxygen saturation of 100%; auscultation indicated that lungs were clear bilaterally. Electrocardiography revealed a normal sinus rhythm and heart rate (45 beats/min) consistent with that of a performance athlete; no signs of right heart strain were apparent. She did not smoke or take oral contraceptives. Secondarily to breathlessness, the patient mentioned general musculo-skeletal pain in her left leg that was attributed to overtraining; no swelling, edema, or collateral superficial veins were apparent. At this time,

the patient commented that leg pain was intermittent and (a) decreased during muscle tissue warm-up (and warm-down) exercises; (b) was not a problem during physical activity; (c) was more obvious after prolonged periods of inactivity (often noticed when resting in bed); and (d) was exacerbated by cold temperatures. The patient had no significant medical history but commented on work-related anxiety, night sweats and polydipsia. She presented with high blood pressure ( $> 140/90$  mmHg) in the Surgery, and white coat hypertension was suspected.

#### Follow-up investigations: exercise-induced asthma (EIA)?

Chest X-rays excluded tuberculosis infection. Resting spirometry together with peak expiratory flow (440 L/min) measurements (before and after exercise) did not evidence EIA. Full blood (including renal and electrolytes, blood glucose, and hemoglobin) and coagulation screens were normal. Ambulatory blood pressure monitoring (24 h average = 122/84 mmHg) was unremarkable.

#### Case progression: additional symptoms and diagnosis

Eight months later, the patient presented immediately after morning training citing worsening dyspnea, deterioration in exercise capacity (lower endurance and longer recovery times) and long-term calf pain (likened to chronic cramping) that could not be alleviated using over-the-counter analgesics. She was distressed by breathlessness and was experiencing chest pain that became sharper upon deep inhalation. The female athlete had been self-administering combinations of ibuprofen, paracetamol, and codeine for 3 months and conceded that these were now having little, if any, effect on the pain in her lower left leg. She recounted that her leg pain had showed no signs of improvement despite a reduction in training demand [shorter (4–8 km) light runs] and the introduction of a full rest day for every 5 days of training; the athlete suspected that she was suffering from a chronic injury. At this time ( $< 1$  h after exercise), dilated superficial veins and marginal swelling ( $< 2$  cm) were apparent in her left leg (Fig. 2); the athlete was hypertensive but bradycardic (45 beats/min).

According to the Wells risk scoring criteria (Tables 1 and 2), the patient's symptoms were not highly consistent with those of VTE; however, she was referred into the DVT fast-track pathway as a precaution. At time of examination in the minor injury unit ( $> 2$  h later), the superficial veins were no longer dilated (Fig. 2) and a low Wells risk score for DVT ( $\leq 1$ ) was recorded (Table 1). In line with protocol, a D-dimer was performed and was found to be significantly elevated (1199  $\mu\text{g/mL}$ ); subsequent Doppler ultrasonography confirmed the presence of DVT in her left popliteal vein (Fig. 3). In view of this highly elevated D-dimer, her

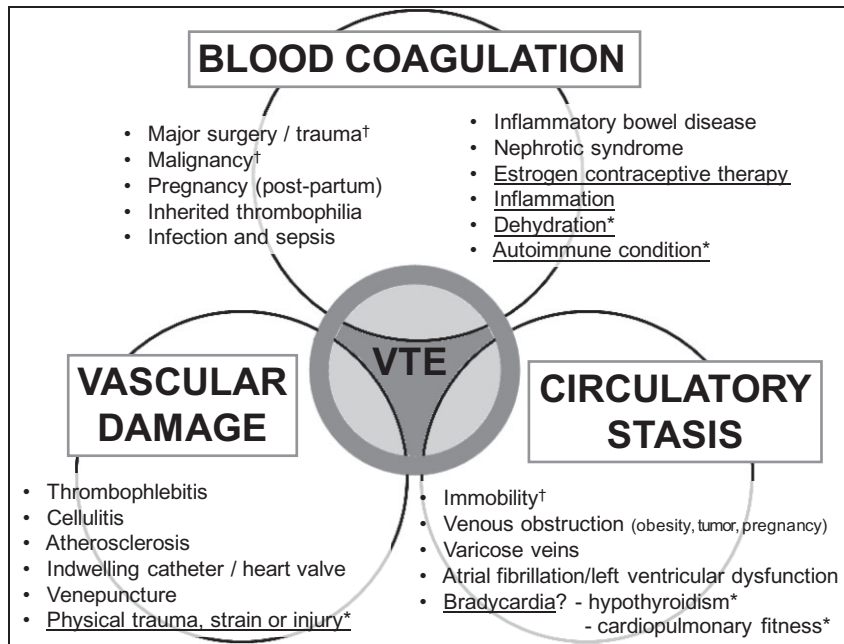


Fig. 1. Critical appraisal of empirical learning theory. Virchow’s triad of risk factors for venous thromboembolism (VTE). Adapted from information in Hull and Harris (2013). Underlined factors are generally applicable to athletes; asterisks indicate possible risk factors for the female athlete in our case study. Note that factors affecting athletes are present in all three sections of the triad; risk of venous thromboembolism in athletes could be additive. The significance of bradycardia in athletes is unknown (?). †Existing Wells score criteria.

chest pain at the time of presentation and the progressive exertional dyspnea reported by the female athlete, she was admitted to hospital for observation (1 week) and 6 months anticoagulation for DVT-PE was initiated on the basis of case history and clinical observations (chest X-ray, Palla’s sign; Fig. 4). Although chest X-ray is not the gold standard for detection of PE (Goldhaber & Morrison, 2002; Goldhaber & Fanikos, 2004), clinical staff decided against further CT scanning in order to minimize radiation exposure and because the extended 6-month anticoagulation course is standard treatment for DVT-PE (vs 3 months anticoagulation for DVT alone). Abdominal ultrasound excluded the presence of fibroids, endometriosis, and polycystic ovaries (classical phenotype).

#### Anticoagulation and return to training

Following discharge from hospital, the athlete refrained from road-running for the entirety of the 6-month anticoagulation period during which time a warfarin (Coumadin) dosage of 9 mg/day was required to maintain an INR of between 2.5 and 3.0. Supplementary daily Clexane (enoxaparin) injections were required for 2 weeks following the initiation of warfarin therapy. A thigh length, class II (18–24 mmHg) compression stocking was worn daily (and removed while in bed) for 12 months; to date, the athlete has not reported any signs or symptoms of post-thrombotic syndrome. During anticoagulation, the female expressed some frustration that

there were no clear return-to-training guidelines and, in view of the unprovoked nature of her thrombotic episode, she expressed concern regarding the training intensity that she should and would be able to undertake in the future. After discussion with a sports physician, the athlete was advised to maintain fitness through power walking (average distance of 8–10 km daily, outdoors) with twice weekly sessions of indoor cycling [20–30-km distances at sustained, moderate (30 km/h) speed]; it was stressed that she should cease exercise immediately if pain or dyspnea was experienced. After the completion of anticoagulant therapy, the athlete gradually returned to more intense training. For the first 2 months, running was only pursued on an indoor treadmill (10-km distances at a comfortable pace) in order to build both stamina and confidence.

#### Discussion

To date, no definitive explanation for the unprovoked DVT-PE has been found. A thrombophilia screen (including antiphospholipid syndrome, prothrombin mutation, protein S, protein C, and factor V Leiden) revealed no abnormalities. Indeed, the possibility that hitherto unforeseen or currently unidentified factors could account for thromboembolism in this athlete remains plausible (Khan & Dickerman, 2006). Advances in our understanding and management of antiphospholipid syndrome since it first came to light (Ruiz-Irastorza et al., 2010) and new insights from

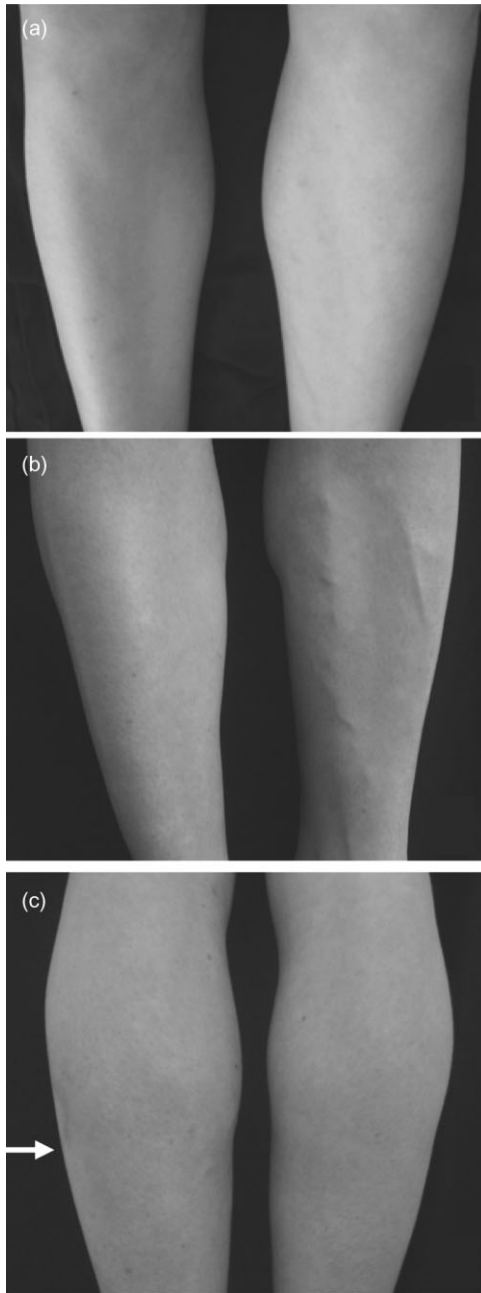


Fig. 2. Deep venous thrombosis in the popliteal vein (left leg). (a) Leg condition before exercise (veins not dilated); (b) immediately after exercise (veins prominent); (c) calf after exercise (marginal swelling).

contemporary research in the area of thrombosis underscore this point.

It is notable that recent (18 months after the thrombotic event) seemingly unrelated investigations for fatigue have indicated subclinical autoimmune hypothyroidism in the female athlete. Here it is again significant that the patient does not present as classical hypothyroid. There is emergent evidence to suggest that autoimmune conditions should be regarded as hypercoagulable disorders (Zoller et al., 2012) and the link between thrombosis and inflammatory markers has received recent attention (Sanjeevi,

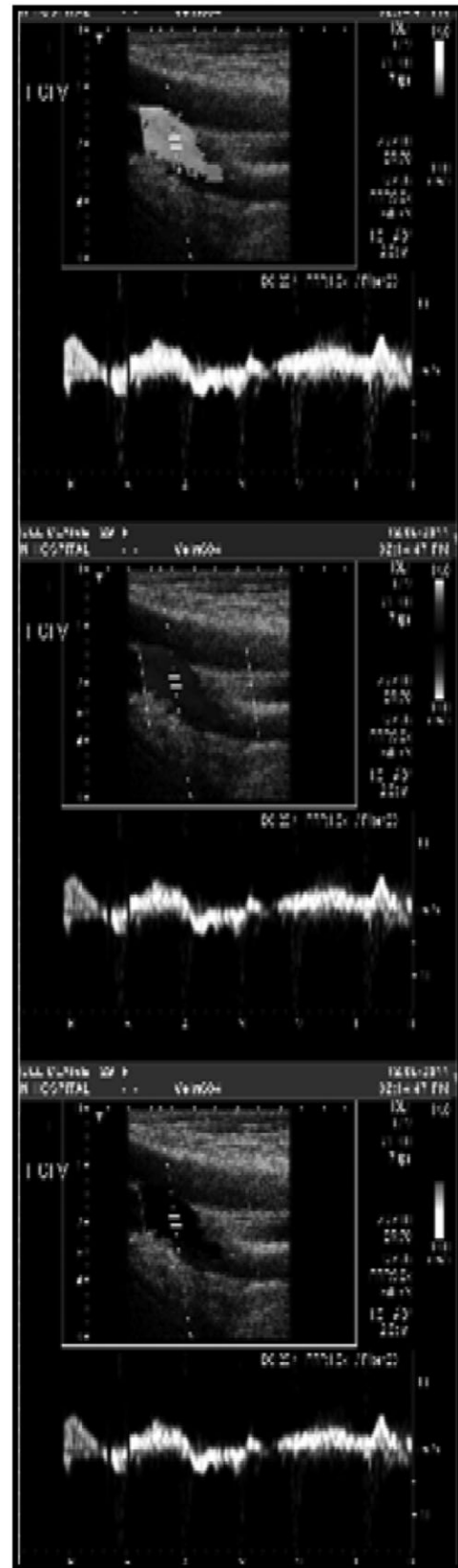


Fig. 3. Duplex ultrasound of the left leg revealed deep thrombosis in the popliteal vein.

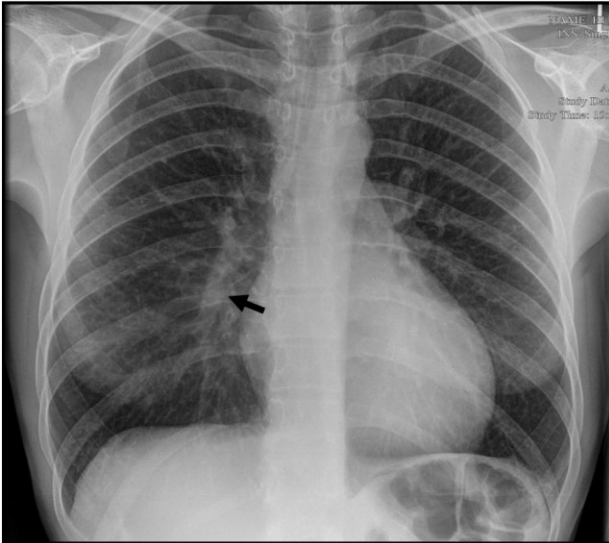


Fig. 4. Chest radiograph showing (black arrow) prominent right descending pulmonary artery (Palla's sign).

2012). In view of our clinical observations, the extent to which hypothyroidism might constitute an additional (or additive) risk factor for thromboembolism in certain athletic patients that possess high cardiopulmonary fitness – by compounding bradycardia and exacerbating venous stasis – warrants further investigation (Fig. 1). Early research that has highlighted potential associations between thyroidal changes and endurance training in women (Boyden et al., 1982, 1984) is relevant and now requires follow-up.

It has been considered that hypothyroidism in the female athlete might have resulted in sensations of fatigue and dyspnea on exertion; however, this explanation does not account for the acute chest pains (consistent with PE) that were experienced upon deep inhalation. It is possible that the popliteal DVT (Figs 2 and 3) may have continuously generated emboli during the 8-month period of ill health and that these were responsible for the progressively worsening exertional dyspnea recounted by the athlete up until the point of DVT fast-track referral. The high cardiopulmonary fitness and/or the activity of natural clot-degradation processes (fibrinolysis) might well have enabled the athlete to compensate for the presence of such pulmonary emboli.

### Diagnostic protocols: no scoring system is definitive

Several of the Wells diagnostic criteria for DVT and PE were not applicable to the subject of this report (Tables 1 and 2). That even a doubling of the patient's resting heart rate (from 45 to 90 beats/min) does not meet the Wells threshold for suspected PE ( $> 100$  beats/min) exemplifies the fact that no scoring system is fail-safe and demonstrates why medical practitioners must remain mindful of the limitations of diagnostic guidelines (Fleming & Fray, 2005). Because they are often bradycardic at baseline

(Tao & Davenport, 2010), the suitability of Wells score cut-off values for athletes may require re-appraisal. It should also be noted that although Palla's sign (enlarged right descending pulmonary artery) was observed (Fig. 4), which can be indicative of pulmonary embolism, its diagnostic specificity, especially in athletes, must be approached with caution. Research into exercise and vasculature suggests that athletes – especially endurance athletes – may exhibit characteristic vascular adaptations including enlarged arteries (larger lumen dimension and decreased wall thickness) relative to healthy nonathletic control subjects (Green et al., 2012).

### Avoiding a missed diagnosis: the athletic patient

The female athlete's primary complaint was exertional dyspnea. This suggests multiple conditions (chest infection, allergy, anxiety), and in athletes, could indicate EIA, vocal cord dysfunction and/or PE (Koehle et al., 2003). That leg pain was initially well tolerated by the patient is perhaps unsurprising given the psychological and physical demands of endurance training. In fact, throughout all investigations, the patient displayed exceptional compensation such that she continued to train right up until the day of DVT fast-track referral. That the athlete described pain-free training intervals is noteworthy because the incidence of occult thromboses that resolve spontaneously is unknown. Symptoms of DVT would typically be expected to present before PE, however, it is quite possible that the athlete reported atypical sequelae because, in the first instance, dyspnea was a greater barrier to performance than leg pain.

Clots can occur in any deep vein (e.g., axillary vein thrombosis) and differential diagnoses for such thromboses include severe superficial bruising, muscular tear, and intramuscular hemorrhage – all of which might apply to an athletic patient (Fleming & Fray, 2005; Tao & Davenport, 2010; Fig. 1). Here, the physical conditioning and pain compensation of athletes may place them at greater risk of a missed diagnosis. Finally, while a negative D-dimer practically rules out thrombosis (Wells et al., 2003), a positive result does not confirm it. The female subject of this case report recently presented again with anxiety over pain in her left leg and was referred into the DVT fast-track pathway. A D-dimer of  $286 \mu\text{g/mL}$  [above local authority cut-off ( $190 \mu\text{g/mL}$ ) for suspected VTE] was recorded but no new evidence for lower extremity thrombosis (excepting indications for the original clot) was identified using Doppler ultrasonography; in this instance, the pain resolved within 3 days and was attributed to muscle strain. It is interesting that portable point-of-care ultrasound for athletes has recently been evaluated (Yim & Corrado, 2013) but that it is not widely available in general practice. Such portable equipment could prove to be a cost-efficient diagnostic resource for medical practitioners and sports physicians in the future and might be especially valuable

for the care of athletes with hereditary thrombophilia and/or for individuals that have experienced an idiopathic thrombotic episode.

#### Long-term management: patient questions and concerns

Some return-to-training guidelines for athletes are documented in the area of sports medicine (Roberts & Christie, 1992; Depenbrock, 2011) but aside from generic advice (e.g., to avoid dehydration), evidence-based recommendations for the general practitioner are lacking. This deficit requires attention because it is usual for athletes to follow specific training routines when injured and because adherence to prescribed targets can help rationalize the anxiety associated with rehabilitation. Regarding hydration in athletes, popular advertisements promote awareness of the need to replenish fluid and electrolytes. However, the regulation and benefits of sports hydration products is controversial (Cohen, 2012). Individual vigilance to dehydration – an obvious risk factor for hemoconcentration – will vary between patients. For the subject of this report, dehydration is perhaps one of the more likely contributory factors (Fig. 1); however its cause is not readily distinguishable. Chronic dehydration leading to hemoconcentration and potentially thrombosis may have resulted from (or been exacerbated by) night sweats, polydipsia, and/or the training demands of the female athlete. Finally, a note on prophylaxis. For individuals with known thrombophilic disorders, anticoagulant drugs are commonly advised (Esponda & Tafur, 2013). For those that experience unprovoked VTE, the guidance is less clear notwithstanding the fact that a second episode entails the prospect of life-long anticoagulation. Prophylactic aspirin may be viable (Siegel, 2012) but its benefits must be weighed against patient-specific risk factors (Lippi et al., 2013).

#### Perspectives

Marathons and related endurance events (e.g., triathlon and Iron Man challenge) continue to attract thousands of enthusiasts and media attention on a global scale. The

heightened risk of arrhythmia and sudden cardiac death in marathon athletes is already well recognized (Link & Estes, 2010; Siegel, 2012). However, despite an increase in relevant but unconsolidated case reports over the last decade (Koehle et al., 2003; Fleming & Fray, 2005; Hurley et al., 2006; Fremont et al., 2007; Kaplan, 2008; Tao & Davenport, 2010; Allana et al., 2011; Theiss et al., 2011; Yim & Friedberg, 2012), the clinical significance of VTE in athletes remains uncharted. It would be prudent to undertake an epidemiological study to compare the risk of VTE in athletes vs nonathletes. Collaborative research with athletics clubs and fitness organizations to establish baseline metrics regarding the prevalence of VTE in athletes (e.g., employing anonymized health questionnaires) constitutes one approach to data acquisition. Additional research in this area could include exercise and physiology monitoring studies (including blood biochemistry) with athletic and nonathletic participants that have suffered unprovoked VTE (and equivalent control groups).

**Key words:** Athlete; deep vein thrombosis; marathon; pulmonary embolism; venous thromboembolism.

#### Acknowledgements

Abertawe Bro Morgannwg University Health Board and staff at Singleton Hospital, Swansea (Ultrasonography, Computer Systems) and Princess of Wales Hospital, Bridgend (Health Records). Colleagues at Swansea University College of Medicine, most especially Dr Jonathan Mullins and Professors Steven and Diane Kelly for their professional support and research funding through the BEACON Convergence project supported by the Welsh Government and the European Regional Development Fund (ERDF) of the European Union.

#### Author contributions

The patient was managed by J.A.H., C.L.H., and R.C.L. C.M.H., N.J.P., and J.A.H. conceived the report. Full permission to use clinical data was given by the patient. All authors prepared the manuscript.

#### References

- Allana AMB, Teo LLS, Chuah BYS, Liu TC, Cheah WK. Effort thrombosis in a young triathlete: an unusual presentation of painless neck swelling secondary to right brachiocephalic vein thrombosis. *Singapore Med J* 2011; 52 (3): e37–e39.
- Boyden T, Pamerter R, Rotkis T, Stanforth P, Wilmore J. Thyroidal changes associated with endurance training in women. *Med Sci Sports Exerc* 1984; 16 (3): 243–246.
- Boyden T, Pamerter R, Rotkis T, Wilmore J. Evidence for mild thyroidal impairment in women undergoing endurance training. *JCEM* 1982; 54 (1): 53–56.
- Cohen D. The truth about sports drinks. *Br Med J* 2012; 345: e4737. doi: 10.1136/bmj.e4737
- Depenbrock PJ. Thromboembolic disorders: guidance for return-to-play. *Curr Sports Med Rep* 2011; 10 (2): 78–83.
- Esponda O, Tafur A. Management of pulmonary embolism: state of the art treatment and emerging research. *Curr Treat Options Cardiovasc Med* 2013; 15 (2): 137–152.
- Fleming A, Fray D. Extensive venous thrombosis in a runner – progression of symptoms key to diagnosis. *Phys Sportsmed* 2005; 33 (1): 34–36.
- Fremont B, Pacouret G, de Labriolle A, Magdelaine B, Puglisi R, Charbonnier B. Exercise deep venous thrombosis:

- myth or reality? About three cases of pulmonary embolism in long-distance runners. *Arch Mal Coeur Vaiss* 2007; 100 (6–7): 519–523.
- Goldhaber SZ, Fanikos J. Prevention of deep vein thrombosis and pulmonary embolism. *Circulation* 2004; 110: e445–e447.
- Goldhaber SZ, Morrison RB. Pulmonary embolism and deep vein thrombosis. *Circulation* 2002; 106: 1436–1438.
- Grabowski G, Whiteside WK, Kanwisher M. Venous thrombosis in athletes. *J Am Acad Orthop Surg* 2013; 21 (2): 108–117.
- Green DJ, Spence A, Rowley N, Thijssen DHJ, Naylor LH. Vascular adaptation in athletes: is there an “athlete’s artery”? Symposium reports – the biomedical basis of elite performance cardiac, respiratory and vascular. *Exp Physiol* 2012; 97 (3): 295–304.
- Hanke AA, Staib A, Goerlinger K, Perrey M, Dirkmann D, Kienbaum P. Whole blood coagulation and platelet activation in the athlete: a comparison of marathon, triathlon and long distance cycling. *Eur J Med Res* 2010; 15 (2): 59–65.
- Hull CM, Harris JA. Venous thromboembolism: awareness information for marathon athletes. *Circulation* 2013; 128: e469–e471.
- Hurley WL, Comins SA, Green RM, Canizzaro J. Atraumatic subdavian vein thrombosis in a collegiate baseball player: a case report. *J Athl Train* 2006; 41 (2): 198–200.
- Kaplan Y. Deep vein thrombosis and the athlete: a case study. *Int J Disabil Hum Dev* 2008; 7 (1): 107–109.
- Khan S, Dickerman JD. Hereditary thrombophilia. *Thromb J* 2006; 4: 15.
- Koehle M, Lloyd-Smith DR, McKenzie DC. Exertional dyspnea in athletes. *BC Med J* 2003; 45 (10): 508–514.
- Link MS, Estes NAM. Athletes and arrhythmias. *J Cardiovasc Electrophysiol* 2010; 21 (10): 1184–1189.
- Lippi G, Sanchis-Gomar F, Cervellin G. Antiplatelet therapy in marathon runners: more harm than benefits? *Am J Med* 2013; 126 (3): E19–E19.
- Meyering C, Howard T. Hypercoagulability in athletes. *Curr Sports Med Rep* 2004; 3 (2): 77–83.
- Roberts WO, Christie DM. Return to training and competition after deep venous calf thrombosis. *Med Sci Sports Exerc* 1992; 24 (1): 2–5.
- Ruiz-Iratorza G, Crowther M, Branch W, Khamashta MA. Antiphospholipid syndrome. *Lancet* 2010; 376 (9751): 1498–1509.
- Sanjeevi CB. Autoimmune diseases and risk of pulmonary embolism. *Lancet* 2012; 379 (9812): 200–201.
- Siegel AJ. Pheidippides redux: reducing risk for acute cardiac events during marathon running. *Am J Med* 2012; 125 (7): 630–635.
- Tao K, Davenport M. Deep venous thromboembolism in a triathlete. *J Emerg Med* 2010; 38 (3): 351–353.
- Theiss JL, Fink ML, Gerber JP. Deep vein thrombosis in a young marathon athlete. *J Orthop Sports Phys Ther* 2011; 41 (12): 942–947.
- Wells PS, Anderson DR, Rodger M, Ginsberg JS, Kearon C, Gent M, Turpie AG, Bormanis J, Weitz J, Chamberlain M, Bowie D, Barnes D, Hirsh J. Derivation of a simple clinical model to categorize patients probability of pulmonary embolism: increasing the models utility with the SimpliRED D-dimer. *Thromb Haemost* 2000; 83 (3): 416–420.
- Wells PS, Anderson DR, Rodger M, Forgie M, Kearon C, Dreyer J, Kovacs G, Mitchell M, Lewandowski B, Kovacs MJ. Evaluation of D-dimer in the diagnosis of suspected deep-vein thrombosis. *NEJM* 2003; 349 (13): 1227–1235.
- Yim ES, Corrado G. Ultrasound in athletes: emerging techniques in point-of-care practice. *Curr Sports Med Rep* 2013; 11 (6): 298–303.
- Yim ES, Friedberg RP. Case report: lower extremity deep vein thrombosis following an intense calf workout. *Curr Sports Med Rep* 2012; 11 (6): 282–286.
- Zoller B, Li X, Sundquist J, Sundquist K. Risk of pulmonary embolism in patients with autoimmune disorders: a nationwide follow-up study from Sweden. *Lancet* 2012; 379 (9812): 244–249.